

**PATIENT**

Lulu Krupnik

**SPECIES**

Feline

**BREED**

DSH

**SEX**

Female Spayed

**AGE**

12 years

**WEIGHT**

8.125lbs

**INTERPRETED BY**Maggie Machen  
Lamy, DVM, DACVIM  
(Cardiology)**HOSPITAL NAME**Alpha Veterinary  
Center**REFERRING VET**

Dr. Cox

**INVOICE**

21335

**DATE**

10/4/21

**PRESENTING CLINICAL SIGNS**

History: Recheck echo. Appetite varies. Originally, owner said that the patient did not tolerate clopidogrel, would foam at the mouth. The patient is on atenolol. This Saturday, 9/18/21, the patient had what sounded like a blood clot event, screaming and not moving. Reinstated Plavix.

-Current medications: Atenolol, 25mg - 1/4-tab, PO BID, Clopidogrel, 75mg - 1/4-tab, PO SID, Buprenorphine, 0.3mg/ml - 0.8ml prn up to BID if patient has another painful episode, Mirtazapine, 15mg - 1/4-tab q72h (the owner breaks the 1/4 tab into smaller pieces per dose - says the cat gets stimulated).

-Sedation used: Not needed.

-Pertinent previous ultrasound results (4/2021 MML): No LVH, no LAE, intermittent LVOTO.

-STAT: Not requested.

**ECHOCARDIOGRAM FINDINGS**

2D, m-mode, color flow and doppler imaging is available. The left ventricular wall is largely normal in dimension with a sigmoid septum. There is a diffusely hyperechoic endocardium consistent with mild fibrosis. The endocardium also appears mildly remodeled. The papillary muscles are normal in size and hyperechoic. The left atrium is normal in size. The right atrium is normal in size. The right ventricle appears normal. The mitral valve is normal in structure and mobility. Trace MR. No other obvious valve regurgitation. Blood flow through the LVOT is normal although some degree of turbulence is noted on color flow imaging. Blood flow through the RVOT is normal in velocity. No pleural or pericardial effusion seen. No obvious cardiac tumors.

**CARDIAC CHART**

FELINE CARDIAC PARAMETERS	BODY WEIGHT (kg)	HR (BPM)	IVSd (cm) <small>(Moise, Pipers)</small>	LVIDd (cm) <small>(Moise, Pipers)</small>	LVWd (cm) <small>(Moise, Pipers)</small>	FS (%)	EF (%)
NORMAL PARAMETER	-----	150-240	3.5-0.55	<2 (mean 1.5)	3.5-0.55	35-67	80-100
PATIENT	3.7	154	0.4	1.6	0.42	36	70
FELINE CARDIAC PARAMETERS	LA/AO (Boon)	LA/AO HEART BASE (Swe) (Abbott)	LA 2D short axis Base view (cm) (Abbott)		LVOT VEL (m/s)	RVOT VEL (m/s)	E max (m/s)
NORMAL	<1.5	<1.3	<1.2		<1.6	<1.3	<0.9
PATIENT	NM	1.2	1.0		1.4	1.0	NM
Adapted from June Boon, Veterinary Echocardiography, 1998 Abbott J & MacLean H JVIM 2006;20: 111-119, Moise et al. Am J Vet Res 47:1476, 1986. Pipers et al. Am J Vet Res 40:882, 1979.							

## INTERPRETATION OF THE FINDINGS & FURTHER RECOMMENDATIONS

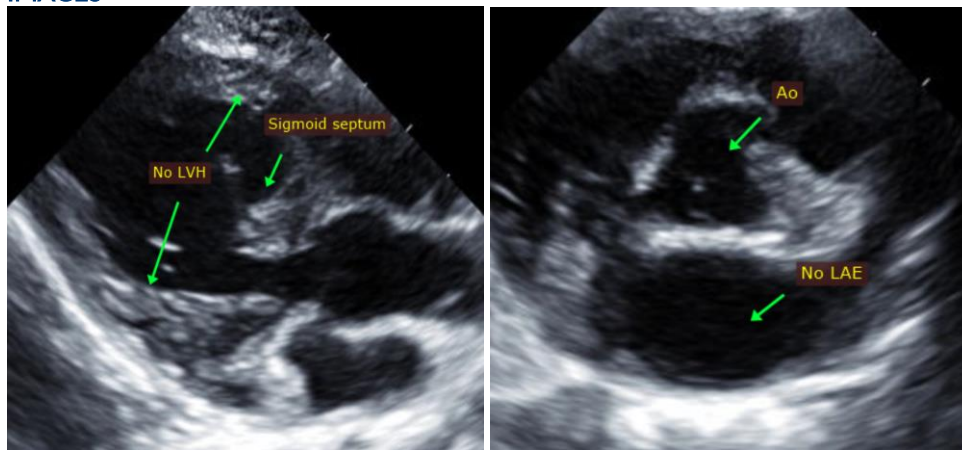
Overtly normal cardiac structure and function persists. Compared to the prior study, there is no significant progression without significant LVH or LA enlargement. An intermittent LVOTO remains suspected which appears benign in origin. Finally, a sigmoid or curved septum is noted, which was not previously documented and may also contribute to the mild LVOTO. No additional issues are identified.

These findings would suggest a cardiogenic thrombus is highly unlikely as the cause of the recent event. Consider other possibilities such as a noncardiac thrombus, neurologic episode, etc. No obvious indication to continue Plavix from a cardiac standpoint; however, further systemic evaluation is advised.

Anesthetic risk is considered mild. With remodeling and diastolic stiffening, there is an elevated risk for fluid overload in this patient and judicious IV fluid use is recommended. Heart rate stimulating drugs such as atropine, glycopyrrolate or ketamine should be avoided unless medically necessary. Risk for complication with steroid use typically follows LA dilation, which in this case is low. That being said, any cat can experience unexpected signs of intolerance and monitoring of RR/RE is advised particularly in the initiation phase.

Recommend recheck echocardiogram in 1 year to assess for any progressive issues.

## IMAGES



The information and recommendations provided are based on the images presented by the referring veterinarian. No evaluation can be communicated regarding pathology that was not visible in the image/video clips provided.

Thank you for this referral. This report was generated using transcription software, and minor dictation errors may be present. If the clinical or image interpretation does not parallel your findings or if I can be of any further assistance, please contact me.

Maggie Machen Lamy, DVM  
Diplomate of the American College of Veterinary Internal Medicine (Cardiology)  
Email: [info@sonopath.com](mailto:info@sonopath.com)